


Homeopathic Treatment of Pododermatitis in Magellanic Penguins (*Spheniscus magellanicus*)

Franscinne Brait Narita^{1,2,4}  Bruna Scardoeli² Hugo Gallo Neto³ Cidéli de Paula Coelho^{2,4}

¹Institute Argonauta para Conservação Costeira e Marinha/Sabina Zoo, Escola Parque do Conhecimento, Santo André, Brazil

²High Dilution Science, São Caetano do Sul, Brazil

³Institute Argonauta para Conservação Costeira e Marinha/Ubatuba Aquarium, Ubatuba, São Paulo, Brazil

⁴Santo Amaro University, São Paulo, Brazil

Address for correspondence Franscinne Brait Narita, Santo Amaro University, Street João Vilhema, 76–Planalto Paulista, São Paulo 04059-040, Brazil (e-mail: fran.b.narita@gmail.com).

Homeopathy 2021;110:62–66.

Abstract

Background Problems with the feet are common in penguins, with a particular predisposition to pododermatitis. This condition usually occurs due to the changes in normal activity that result from being held captive, but its precise pathogenesis is still undetermined.

Methods/Patients This veterinary case study reports the use of oral homeopathic treatment on acute and chronic pododermatitis in five Magellanic penguins in a zoological park setting. During treatment, the patients remained in the penguins' living area, and the effect of the treatment on the progression of their lesions was assessed visually once weekly. The treatment consisted of a combination of *Arnica montana* and *Calcarea carbonica*.

Results After treatment, the appearance of the lesions had noticeably improved: in the majority of penguins there was no longer evidence of infection or edema in the feet. The rate of recovery depended on the initial severity of the lesion. Those penguins that still showed signs of infection nevertheless exhibited a clear diminution of the size and thickness of the lesions. Homeopathic treatment did not cause any side effects.

Conclusion Homeopathy offers a useful treatment option for pododermatitis in captive penguins, with easy administration and without side effects.

Keywords

- ▶ veterinary homeopathy
- ▶ penguins
- ▶ pododermatitis
- ▶ zoological park

Introduction

Penguins are seabirds from the *Spheniscidae* family, distributed in the southern hemisphere.¹ They are predisposed to pododermatitis, also called bumblefoot, which is a generic term that can be used to describe any organic process in the pelvic limbs, from simple stiffening to chronic abscessation. Various etiologies have been suggested.^{2,3}

This condition exhibits a high morbidity in captive penguins due to their sedentary lifestyle with its associated decrease in swimming time, leading to an increase in body weight. Consequently, the birds spend long periods standing on abrasive, damp, and fecally contaminated floors. The overall effect is that the individuals deposit their body

weight on the lower limbs for a longer period of time and this impairs the circulation to the area of the foot, causing hypoxia and thus accelerating cell necrosis.^{1,4,5}

The breakdown of the epithelial barrier associated with ulcerative lesions permits colonization of the subcutis by pathogenic micro-organisms present in the environment, the skin and the digestive and respiratory tracts, resulting in the formation of abscesses, edema, laminitis, osteomyelitis, and septicemia. The most common micro-organism isolated is *Escherichia coli*.

Assessment requires an evaluation of the animal's posture along with identification of epithelial wear, lacerations, ulcerations, swelling, local temperature increase, hyperemia, pain on palpation, and radiographic changes.^{1,6}

received

February 25, 2020

accepted after revision

June 26, 2020

published online

December 14, 2020

© 2020. The Faculty of Homeopathy.

All rights reserved.

Georg Thieme Verlag KG,

Rüdigerstraße 14,

70469 Stuttgart, Germany

DOI <https://doi.org/>

10.1055/s-0040-1716392.

ISSN 1475-4916.

The present study reports on the homeopathic treatment of acute and chronic pododermatitis in five Magellanic penguins (*Spheniscus magellanicus*) that were resident in the Sabina Zoo (Institute Argonauta, Santo André, Brazil).

Methods/Patients

Of the 28 penguins residing in the zoo, five were identified as suffering from acute or chronic pododermatitis. Of these, four had a history of relapsing at least once a year. Penguins numbers 093, 096 and 099 had been treated conventionally since 2009, and 004 since 2012. Penguin No. 029, still juvenile, presented with lesions in its first year of life. In general, the previous treatments were based on DMSO, a systemic and anti-inflammatory antibacterial, which produced temporary improvement, but there was recurrence within a few months.

There are three clinical grades to classify pododermatitis: grade I is characterized by mild and localized lesions that often affect only a single digit, and the patient remains asymptomatic or with mild lameness and hyperthermia to the touch; in grade II, the infections are more extensive, with bacterial infiltration causing increase in temperature and volume by means of serous exudate—lameness is more evident, with affected animals lying down or favoring the uninjured limb; in grade III, the intense involvement provokes pain and high local temperature—the patient cannot use the limb because of intensifying discomfort and, if the condition is not treated correctly, the condition can lead to death.^{7,8}

This veterinary case study was authorized by the Institute Argonauta/Sabina Zoo, including consent to use the data for scientific purposes (► **Supplementary File 1**, available online only), and reported using criteria established in the homeopathic clinical case reporting (HOM-CASE) guidelines.⁹ The evolution of these cases was documented photographically.

Three penguins had pododermatitis only, and two had pododermatitis plus osteomyelitis. Different homeopathic treatment regimens were chosen for the two groups. On the first day of treatment, photographs were taken of the feet, and calipers were used to measure the lesions. Each patient was then classified as to the degree of pododermatitis. During the treatment, the penguins remained in their living area and once a week each one was evaluated with an assessment of their lesions and hence the effectiveness of the treatment. Those patients with uncomplicated pododermatitis received *Arnica montana* 6cH, administered twice daily; those that presented with concurrent osteomyelitis also received *Arnica montana* 6cH but in association with *Calcarea carbonica* 12cH, twice daily. The medication was administered hidden in the penguins' food (fish), this being a practical and effective way of administering medicines to wild animals. The treatment did not include the use of any orthodox medications.

Results

Penguin numbers 004 (► **Fig. 1A, B**), 029 (► **Fig. 2A, B**), and 099 (► **Fig. 3A, B**) had only pododermatitis, whilst penguin numbers 093 (► **Fig. 4A, B**) and 096 (► **Fig. 5A, B**) had associated osteomyelitis. Before homeopathic treatment,

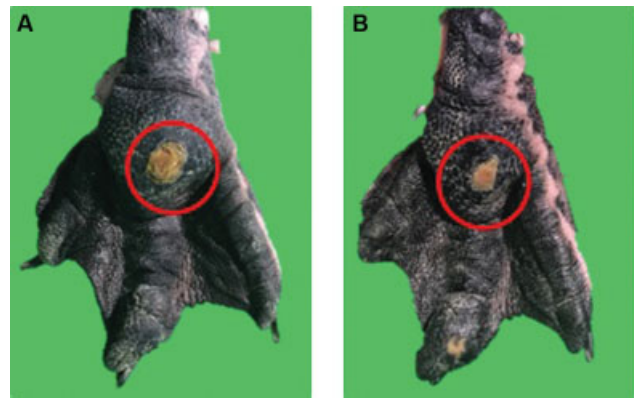


Fig. 1 Degenerative pododermatitis regression. Penguin number 004 (A) before the treatment on May 2, 2018 and (B) after treatment on June 21, 2018. Source: Author's personal archives, 2018.

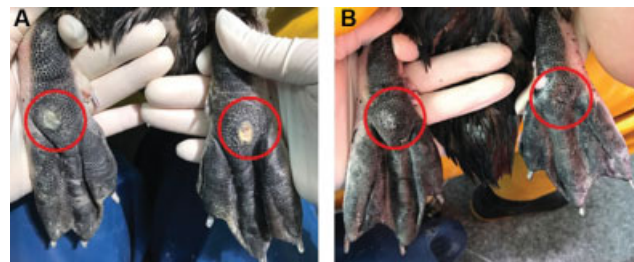

Fig. 2 Degenerative pododermatitis regression. Penguin number 029 (A) before the treatment on October 13, 2018 and (B) after treatment on November 30, 2018. Source: Author's personal archives, 2018.

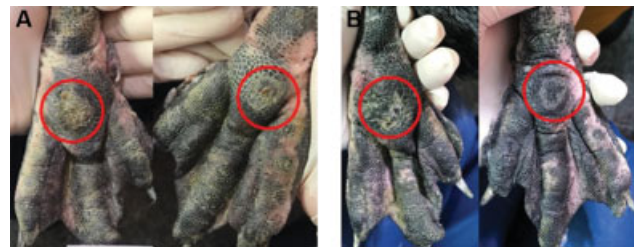

Fig. 3 Degenerative pododermatitis regression. Penguin number 099 (A) before the treatment on October 13, 2018 and (B) after treatment on November 20, 2018. Source: Author's personal archives, 2018.

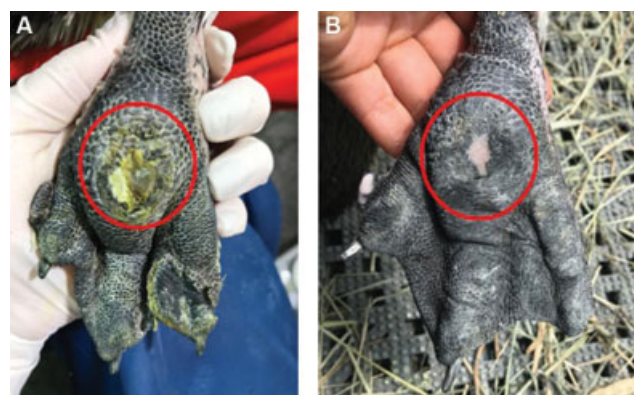


Fig. 4 Proliferative pododermatitis regression. Penguin number 093 (A) before treatment on October 9, 2018 and (B) after treatment on November 30, 2018. Source: Author's personal archives, 2018.

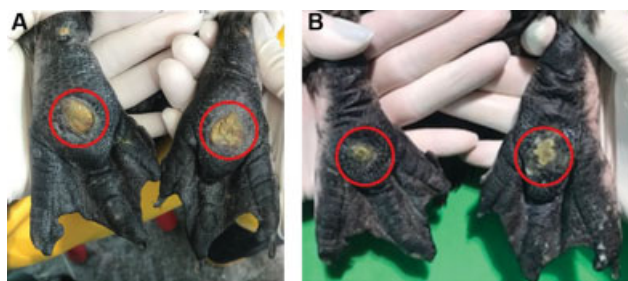


Fig. 5 Proliferative pododermatitis regression associated with osteomyelitis improvement. Penguin number 096 (A) before treatment on April 9, 2018 and (B) after treatment on August 21, 2018. Source: Author's personal archives, 2018.

penguin number 004 presented degenerative pododermatitis in its right limb with a single localized lesion without increased temperature but accompanied by a little increase in volume without accumulation of serous exudate. Penguin numbers 029 and 099 presented with degenerative pod-

dermatitis with a single localized lesion in both feet without increased temperature, volume, or accumulation of serous exudate. Penguin numbers 093 and 096 both presented with lameness due to the proliferative pododermatitis in their left limb, with a single localized lesion without increased temperature or volume associated with serous exudate. Further details are provided in ►Table 1.

The treatment for all penguins was effective (►Figs. 1B, 2B, 3B, 4B, 5B). The speed of treatment was related to the degree of injury: recovery for the three patients with grade I and II lesions was shown by extreme agility within 30 to 45 days of treatment, whilst in the other two animals, in grade III and already affected by osteomyelitis, the progression of recovery was slower, ranging from 50 to 70 days. Evidence by caliper measurements of the diminution of lesion size is illustrated by examples for penguin numbers 004 and 096 (►Supplementary Files 2 and 3, respectively; available online only). No side effects from the homeopathic treatment were observed, nor any kind of stress on handling (►Table 1).

Table 1 Case summary based on HOM-CASE guidelines

	Penguin 004	Penguin 029	Penguin 099	Penguin 093	Penguin 096
Patient	Male, 10 years old	Male, 2 years old	Male, 10 years old	Male, 10 years old	Female, 10 years old
Presenting date	May 2, 2018	October 13, 2018	October 13, 2018	September 10, 2018	August 21, 2018
Medical history	<i>Topical use:</i> Ointments with gentamicin sulfate; penicillin, urea and dihydrostreptomycin, and hydrogel with neomycin. <i>Oral use:</i> Dimethyl sulfoxide; enrofloxacin; ketoprofen; meloxicam.	<i>Topical use:</i> Ointments with gentamicin sulfate; penicillin, urea and dihydrostreptomycin, and hydrogel with neomycin. <i>Oral use:</i> Dimethyl sulfoxide; enrofloxacin; ketoprofen; meloxicam.	<i>Topical use:</i> Ointments with gentamicin sulfate; penicillin, urea and dihydrostreptomycin; and hydrogel with neomycin. <i>Oral use:</i> Dimethyl sulfoxide; enrofloxacin; ketoprofen; meloxicam.	<i>Topical use:</i> Ointments with gentamicin sulfate; penicillin, urea and dihydrostreptomycin; and hydrogel with neomycin. <i>Oral use:</i> Dimethyl sulfoxide; enrofloxacin; ketoprofen; meloxicam.	<i>Topical use:</i> Ointments with gentamicin sulfate; penicillin, urea and dihydrostreptomycin; and hydrogel with neomycin. <i>Oral use:</i> Dimethyl sulfoxide; enrofloxacin; ketoprofen; meloxicam.
Physical examination	Degenerative pododermatitis without increasing temperature but accompanied by increased volume.	Degenerative pododermatitis without increasing temperature, volume and serous exudate.	Degenerative pododermatitis without increasing temperature, volume and serous exudate.	Proliferative pododermatitis with serous exudate, associated with lameness.	Proliferative pododermatitis with serous exudate, associated with lameness.
Working diagnosis	Pododermatitis; osteomyelitis; abscess.	Pododermatitis; osteomyelitis; abscess.	Pododermatitis; osteomyelitis; abscess.	Pododermatitis; osteomyelitis; abscess.	Pododermatitis; osteomyelitis; abscess.
Pertinent laboratory findings	Antibiogram and blood test.	Antibiogram and blood test.	Antibiogram and blood test.	Antibiogram and blood test.	Antibiogram and blood test.
Final diagnosis	Pododermatitis Grade II	Pododermatitis Grade I	Pododermatitis Grade I	Pododermatitis and osteomyelitis Grade III	Pododermatitis and osteomyelitis Grade III
Treatment	<i>Arnica montana</i> 6cH twice a day.	<i>Arnica montana</i> 6cH twice a day.	<i>Arnica montana</i> 6cH twice a day.	<i>Arnica montana</i> 6cH and <i>Calcarea carbonica</i> 12cH, twice daily.	<i>Arnica montana</i> 6cH and <i>Calcarea carbonica</i> 12cH, twice daily.
Course of treatment response	Proliferative pododermatitis regression	Proliferative pododermatitis regression	Proliferative pododermatitis regression	Proliferative pododermatitis regression	Proliferative pododermatitis regression
Follow-up	Patient has not presented any recurrence after the regression.	Patient has not presented any recurrence after the regression.	Patient has not presented any recurrence after the regression.	Patient has not presented any recurrence after the regression.	Patient has not presented any recurrence after the regression.
Side effects	No side effects from the homeopathic treatment were observed.	No side effects from the homeopathic treatment were observed.	No side effects from the homeopathic treatment were observed.	No side effects from the homeopathic treatment were observed.	No side effects from the homeopathic treatment were observed.
Figure	1A and B	2A and B	3A and B	4A and B	5A and B

Abbreviation: HOM-CASE guidelines, homeopathic clinical case reporting guidelines.

Discussion

Orthodox treatment of pododermatitis includes topical anti-inflammatory and anti-edematous medication (for example, DM-Gel, composed of dimethyl sulfoxide, dexamethasone, prednisolone and lidocaine), surgical excision, cryotherapy, analgesics, ointment and bandaging after debridement of devitalized tissue, and the use of neoprene boots. Duration of treatment varies from 1 to 3 months; however, it can extend to 2 or 3 years.¹⁰ Systemic antibiotics should be used only for the most serious infections, both to avoid the development of bacterial resistance and to minimize the side effects associated with this type of therapy.⁷ In general, pododermatitis is caused by fecal contamination causing infection by *Escherichia coli* and *Proteus sp.*: hence enrofloxacin and clindamycin are the most commonly used antibiotics.^{11–13} When osteomyelitis occurs, prognosis is severely impaired,¹⁴ requiring treatment with systemic antibiotic therapy and surgery of the cutaneous lesion, with bandage changes at intervals of 2 to 3 days for at least 1 week. After resolution, a preventative regimen should be installed.¹³

Penguins are hypersensitive to orthodox treatments, however: damaging side effects can occur, and other medications may be prescribed to minimize those. Ultra-diluted homeopathic medications are used in our zoo as a substitute for antibiotics when the animal develops bacterial resistance or when the illness has a tendency to recur. There is evidence that such treatments can modulate the immune response of the host organism, allowing it to fight the infection.^{14,15} Another drawback of conventional therapy is the stress induced in the animals at the time of changing bandages, for example. Penguins in zoos are kept in a living environment that strives to simulate their natural habitat, but they still behave as preyed animals, so when it comes to daily medical care, their stress can increase, sometimes disturbingly. When a treatment is administered through food, as it is with homeopathy, the stress from capturing is eliminated.

Arnica montana is the most suitable homeopathic medicine for trauma and, despite its short duration of effect, can have immediate anti-inflammatory and anti-infectious action. It is indicated for post-operative pain, dislocations, fractures, bruises, edema, and other conditions where pain is intense. Its action makes it suitable for use in conditions of traumatic origin and muscle fatigue, as well as in pathologies that affect capillaries and veins.¹⁶ *Calcarea carbonica* may be prescribed for poor bone quality, secondary nutritional hyperparathyroidism, relaxation of muscles and veins, spinal deviation, rheumatism of the extremities, swollen joint disorders, severe limb weakness, and rigidity throughout the body.^{17,18} It acts on the general metabolism, bone tissue (as in exostoses, deformations and decalcifications), and lymphoid tissue.¹⁶

Independent of the kind of treatment chosen, the time necessary to treat pododermatitis depends on the grade of the injury. For all five penguins that we studied, the exterior aspect of the injuries had noticeably improved. For penguins 029, 099, and 093, there was no more sign of infection, nor edema in the feet area. Even where there were still signs of

infection, there was clear diminution of the size and thickness of the lesions, and there was no longer any sign of edema in the plantar area; this was especially apparent for penguins 004 and 096. It should be noted, however, that this study was not randomized or controlled, which can be seen as a limiting factor; nevertheless, our reported observations are worthy of attention and can help in the design of future rigorous controlled studies.

Conclusion

This study shows that well-selected homeopathic medicines may provide an effective treatment option for pododermatitis in penguins. The remedies are easy to administer and they produced no side effects.

Supplementary Figures

Supplementary File 1 Authorization letter, Sabina Zoo.

Supplementary Fig. 1 Degenerative pododermatitis regression measured with a caliper.

Supplementary Fig. 2 Proliferative pododermatitis regression associated with osteomyelitis improvement measured with a caliper.

Conflict of Interest

None declared.

References

- 1 Fowler ME. *Biology, Medicine and Surgery of South American Wild Animals*. 1st ed. Iowa: Iowa State University Press; 2001
- 2 Hocking PM, Mayne RK, Else RW, French NA, Gatcliffe J. Standard European footpad dermatitis scoring system for use in turkey processing plants. *Worlds Poult Sci J* 2008;64:323–328
- 3 American Zoo and Aquarium Association. *Penguin (Spheniscidae) Care Manual*. Silver Spring, MD: Penguin Taxonomy Advisory Group; 2005
- 4 Cubas ZS. Order Sphenisciformes (Penguins) biology, captive management, and medicine. In: Fowler GS, Fowler ME, eds. *Biology, Medicine and Surgery of South American Wild Animals*. 1st ed. Iowa: Iowa State University Press/Ames; 2001:53
- 5 Girling S. Veterinary nursing of exotic species. *J Wildl Dis* 2008; 44:1059–1060
- 6 Reisfeld L, Barbirato M, Ippolito L, et al. Reducing bumblefoot lesions in a group of captive Magellanic penguins (*Spheniscus magellanicus*) with the use of environmental enrichment. *Pesqui Vet Bras* 2013;33:791–795
- 7 Cooper JE. *Birds of Prey: Health and Disease*. 3rd ed. UK: Blackwell; 2002
- 8 Harcourt BN. Bumblefoot. In: Samour J, ed. *Avian Medicine*. 3rd ed. London: Mosby-Harcourt; 2000:121–131
- 9 van Haselen RA. Homeopathic clinical case reports: development of a supplement (HOM-CASE) to the CARE clinical case reporting guideline. *Complement Ther Med* 2016;25:78–85
- 10 Jacob SW, Torre J. *Dimethyl Sulfoxide (DMSO) in Trauma and Disease*. 1st ed. Florida: CRC Press; 2004
- 11 Carpenter JW, Mashima TY, Rupiper DJ. *Exotic Animal Formulary*. 2nd ed. Philadelphia: W.B. Saunders; 2001

- 12 Cubas ZS, Silva JCR, Dias JLC. Tratado de Animais Selvagens-Medicina Veterinária. Vol.1. 1st ed. São Paulo: Roca; 2014
- 13 Ritchie BW, Harrison GJ, Harrison LR. Avian Medicine: Principles and Application. 1st ed. Florida: Wingers Publishing; 1994:950–982
- 14 Coelho CdP, Motta PD, Petrillo M, et al. Homeopathic medicine *Cantharis* modulates uropathogenic *E. coli* (UPEC)-induced cystitis in susceptible mice. *Cytokine* 2017;92:103–109
- 15 Passeti TA, Bissoli LR, Macedo AP, Libame RB, Diniz S, Waisse S. Action of antibiotic oxacillin on in vitro growth of methicillin-resistant *Staphylococcus aureus* (MRSA) previously treated with homeopathic medicines. *Homeopathy* 2017;106:27–31
- 16 Demarque D. Homeopatia: Medicina de Base Experimental. Tradução de Edméa Marturano Villela e Izaio Carneiro Soares, 2nd ed. Ribeirão Preto: Museu de Homeopatia Abrahão Brickmann; 2002
- 17 Torro AR. Homeopatia Veterinária: Semiologia, Materia Médica e Psicossomática. 1st ed. São Paulo: Typus Editora e Distribuidora; 1999
- 18 Lathoud JA. Estudos de Materia Médica Homeopática. 3rd ed. São Paulo: Organon; 2017